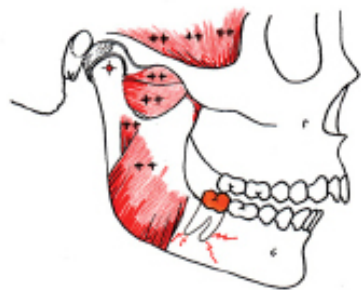


How Disharmony Between the TMJs and the Occlusion Causes Harm

Peter E. Dawson, DDS

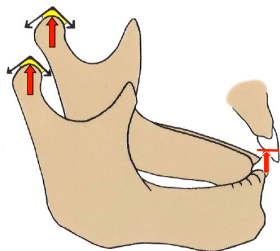
If I were writing the curriculum for a four-year dental education, I would start in the freshman year by asking the question, “How does disharmony between the TMJ’s and the occlusion cause harm?” I would then tell every student that this question will be a dominant centerpiece for their dental education. I would let them know that during their four years, they will be expected to understand the answer to this question so clearly that when they start practice they will be at a tremendous advantage over more than 90% of the “usual and customary” dentists.

Excuse my political incorrectness for being so blunt...but a dentist who does not understand the relationship between occlusion and the TMJs can never be better than a mediocre dentist. Let me explain why.



Disharmony between the TMJ’s and the occlusion is responsible for excessive tooth wear, fractured teeth, loose teeth, teeth that shift out of position. This disharmony is also the single most common cause of discomfort and patient dissatisfaction with the dentistry that is done. If this sounds like an exaggeration I can assure you it is not. I can tell you from many years of treating thousands of patients, and working with thousands of dentists in our curriculum at The Dawson Academy that an understanding of occlusion is life changing for any dentist, regardless of specialty.

Let’s start with an understanding of what a perfected occlusion looks like. An oversimplified formula is “Lines in front...Dots in back”. What does this mean? It means that when the jaw closes to maximum tooth contact (MIP), both condyle/disc assemblies are completely seated up as high as they can go into their respective sockets. This is called centric relation and it is the starting point for everything that we do with an occlusion.

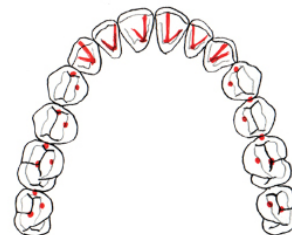


Stopping points for jaw closure
in a perfected occlusion

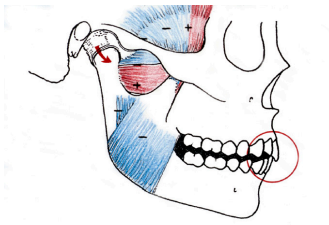
The second thing we look for in a perfected occlusion is proper contact of the lower incisors with the upper incisors in centric relation. Next, we do not want premature contact of any back tooth before the condyles are completely seated and the anterior teeth are in contact. This results in equal intensity, simultaneous contact of all the teeth, including the front teeth in centric relation. If the condyle’s are completely seated at this described tooth contact, it is impossible to overload any tooth. That is the essential starting point for a perfected occlusion.



Peter E. Dawson, D.D.S. is considered to be one of the most influential clinicians and teachers in the history of dentistry. He authored the best selling dental text, *Evaluation, Diagnosis and Treatment of Occlusal Problems*, which is published in 13 languages. His latest book is entitled *Functional Occlusion: From TMJ to Smile Design*. He is the founder of the “Concept of Complete Dentistry Seminar Series[®]” as well as The Dawson Academy. In addition to numerous awards and special recognitions, Dr. Dawson is the past president and life member of the American Equilibration Society, a past president of the American Academy of Restorative Dentistry and the American Academy of Esthetic Dentistry.



The formula for a perfected occlusion



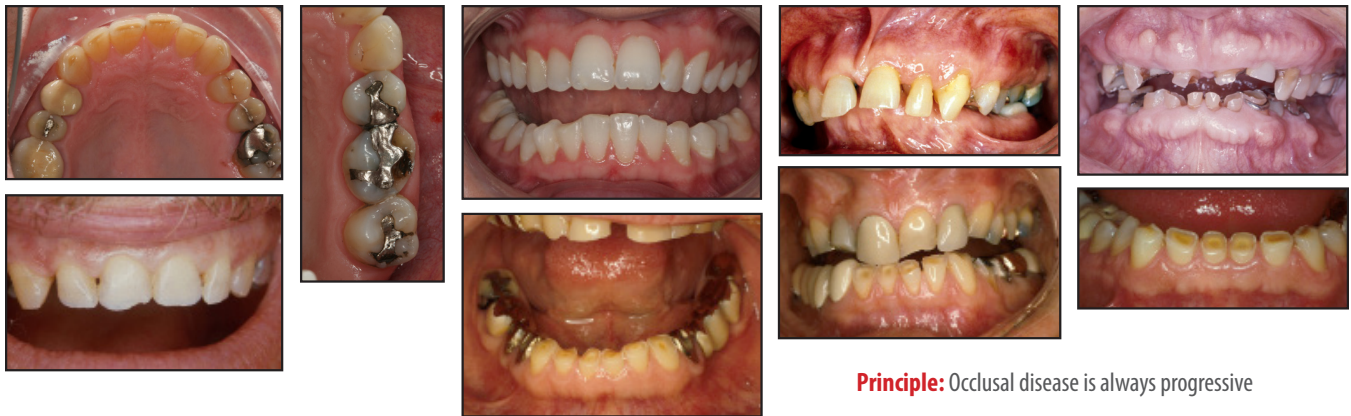The Goal: Immediate disclusion

After that ideal starting point is achieved, the next goal is for the anterior guidance to immediately separate all the posterior teeth at the moment the mandible moves from centric relation in any direction. This is called “immediate posterior disclusion”. If you put a marking ribbon between all the teeth and have the patient squeeze hard and move their jaw in all directions there will be lines on the front teeth as those inclines are used to separate the back teeth in all jaw positions except when the condyles are completely seated in centric relation. This is what makes “lines in front . . . dots in back”.

Why is this considered the ideal? Because in a perfected occlusion with immediate posterior disclusion, it is impossible to overload the posterior teeth. It is impossible to wear posterior teeth. It is impossible to create horizontal forces on posterior teeth that can work them loose or move them. The simple explanation is: You cannot wear what you cannot rub.

Understanding the above makes the answer to our original question simple to understand:

If the back teeth are in the way of how the jaw moves, or if the anterior guidance can not separate the back teeth when the jaw moves from centric relation, the back teeth are not only in a position of vertical overload, they are also subject to lateral forces that they aren’t made to resist. The result is what we call “occlusal disease”. Occlusal Disease comes in many different forms, any one of which is undesirable.



Principle: Occlusal disease is always progressive

Now I have oversimplified both the question and the answer, because in order to accomplish a perfected occlusion you must understand the temporomandibular joints. You must understand when they are or are not stable . . . and you absolutely must understand when they are seated in their physiologic, uppermost position of centric relation. If you didn’t learn all this in dental school, it is not too late. The curriculum at The Dawson Academy is here to answer all the questions you might have in addition to teaching you the skills necessary for finding and verifying centric relation. Also you can learn the precisely accurate methodology for determining an exactly correct anterior guidance. Incidentally that is also the key to establishing the very best smile design.

And I can promise you this...your life as a dentist will never be the same when you learn what it is like to be predictable in every thing you do for a patient...not to mention the added production that comes when you eliminate remakes, reworks and making excuses to patients.

At the Dawson Academy, we love to make good dentists even better. Come see us.

Yours for an exciting practice,

Pete Dawson