International Journal of Scientific Study

Short Communication

Periodontal Maintenance Program in Orthodontic Patients

Fulari Sangamesh G[1], Revankar Siddharth[2], Shivnaikar Sachin[3]

1 MDS, Orthodontics and Dentofacial Orthopedics, Maratha Mandals N. G. H Institute of Dental Sciences and research Centre Belgaum,Karnataka, India. **2** MDS, Orthodontics and Dentofacial Orthopedics, Maratha Mandals N. G. H Institute of Dental Sciences and research Centre, Belgaum, Karnataka, India. **3** MDS, Periodontics Maratha Mandals N. G. H Institute of Dental Sciences and research Centre, Belgaum, Karnataka, India

Abstract

Periodontal problems are commonly seen during and post orthodontic treatment. A proper interdisciplinary treatment plan along with periodontal maintenance has led to successful orthodontic treatment in even periodontally compromised patients. Every patient should be educated and positively motivated not only to avoid occurrence of periodontal problems but to create awareness and help in achieving a healthy periodontium. This article presents an overview on few common maintenance aids towards promotion of oral health in orthodontically treated patients.

Keywords: Periodontium, Interproximal, Decalcification

Introduction:

In today's aesthetic world patients seeking orthodontic treatment is considerably increasing. Outcome of the success of treatment largely depends on the periodontal status of patients. Fixed orthodontic appliances increase the risk of plaque accumulation posing a potential damage to teeth, gingiva and alveolar bone. Periodontal maintenance should be carried out before, during and after orthodontic treatment. This article presents an overview on proper inter-disciplinary approach and positive reinforcement with the patients aiming for maintenance of the health of the periodontium in orthodontically treated patients.

Periodontal Tissues in Orthodontic Treatment:

Fixed orthodontic appliances would make brushing procedure difficult hence inability to completely remove plaque initiates the potential to cause gingivitis and progress to periodontitis during tipping and extrusive movements [Figure 1]. The gingival pocket deepens and results in development of pseudo pockets [Figure 2]. This pseudo pockets provides an opportunity for colonization to subgingival bacteria leading to periodontal breakdown.[1, 2] This periodontal destruction overtime undergoes some degree of degeneration in PDL. Force applied on such teeth can result in more periodontal breakdown and regeneration of periodontal ligament tissues with periodontal inflammation present are defenseless to bacterial infection.[3, 4]

Removable appliances have however not been shown to cause such periodontal liability because of ease of cleansing with the appliances.[5] Trauma from occlusion, one of the major factors causing periodontal problems should be relieved to avoid any further progress of the disease. These gingival problems and periodontal breakdown once occurred may present themselves in extension or increments.

However, if effective preventive measures are taken by the operator and patients during treatment, no clinically significant damage to the periodontuim will occur.[6, 7]



Figure 1: Gingivitis Due to Crowding

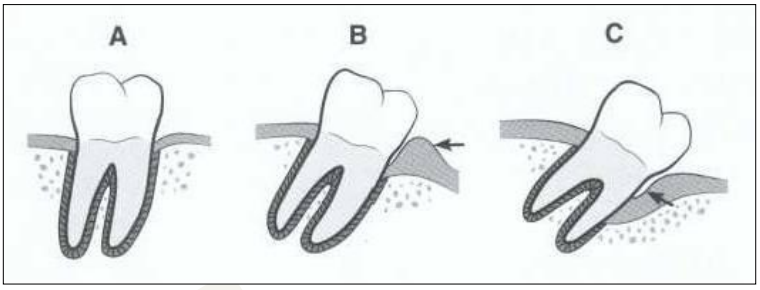

Figure 2: Formation of pseudo pockets

A) Upright molar in normal position.
B) Soft tissue piling up on mesial surface as molar tips forming pseudo pocket.

As pseudo pocket deepens subgingival plaque accumulation occur's leading to periodontitis.

Treatment Program:

Every patient should be properly screened and after initial diagnosis, referral for treatment to control active periodontal disease and caries should be done. Patients should be explained about the treatment, their responsibilities and risk during orthodontic treatment. Proper instructions and positive reinforcement about management of new oral environment and its maintenance must be emphasized. Provide the patients with initial brushing and flossing instructions with either a conventional or powered tooth brush. A fluoride tooth paste and chlorhexidine mouthwash for antigingivitis and anti plaque effect should be advised. Regular appointments scheduled increase the patient's compliance towards treatment. Additional methods to improve oral hygiene such as flossing should be introduced. Patient's routine dental appointments and periodontal status information chart will help in knowing the progress of periodontal disease and explaining the importance of its maintenance. A poor compliant patient needs more professional time explaining the ill effects of poor oral hygiene. Before start of orthodontic treatment, patients should undergo supragingival and subgingival scaling, and root planning if necessary.[8]

Plaque Removal:

Toothbrushes: Presence of brackets, archwires and ligatures make brushing more difficult. Conventional tooth brushes having soft bristles with rounded ends to minimize gingival and tooth abrasion should be advised. Brushes with shorter middle row bristles than the outer one are specific for orthodontic treatment purpose. A clinician should properly train the patient in brushing habits [Figure 3, 4]. Brushing should be accomplished with gentle vibratory movements at one place and avoid scrubbing and cleaning behind the archwires and cleaning of inter proximal areas to be emphasized. A modified bass method with bristles at 45 degrees to sulcus would be more beneficial in patients with deepened pockets. Patients should be made to demonstrate the method of brushing and must be made aware when appliances are shiny are clean.

Electric toothbrushes: The Rotadent electric toothbrush with short pointed bristles was found to be more effective than conventional toothbrushes in orthodontic patients. It was seen to remove the interproximal plaque more effectively with least abrasion because of smaller diameter bristles.[9,10] However due to cost effectiveness it was often neglected by the patients [Figure 5].

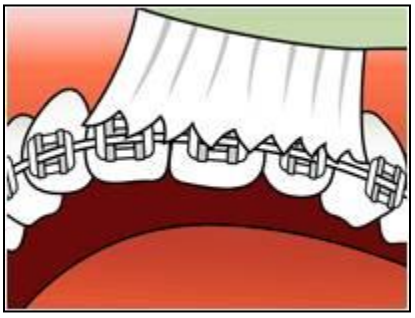

Figure 3: Brushing techniques.
3- A: Placing bristles where gums and teeth meet.

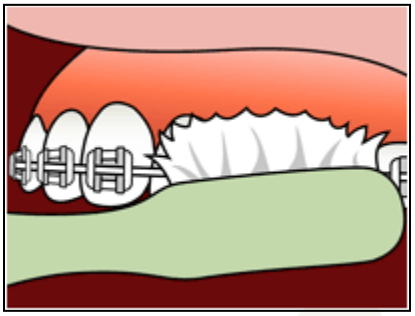

Figure 3-B: Circular and gentle vibratory motions around gum lines on each tooth.

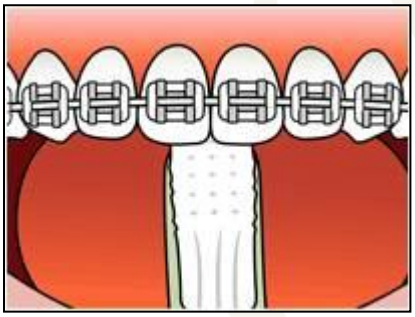

Figure 3-C: Slow brushing on palatal/lingual surfaces of each tooth.



Figure 3-D: Brush from gum line to occlusal surface.

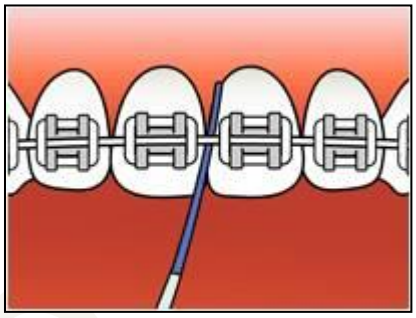

Figure 4: Flossing technique
4-A: Thread unwaxed floss between braces & wire.

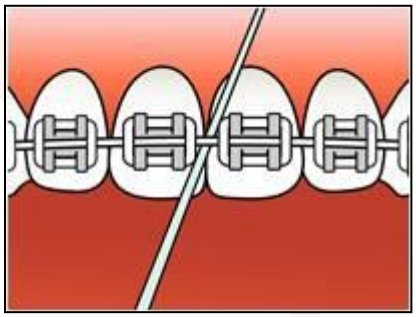

Figure 4-B: Floss around braces.

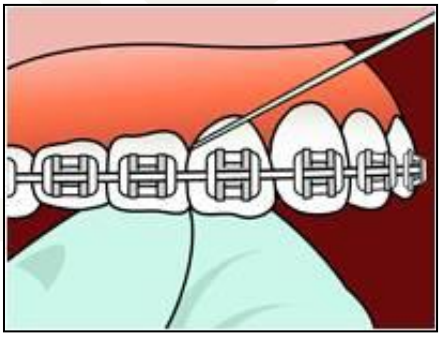

Figure 4-C: Floss around gum areas.

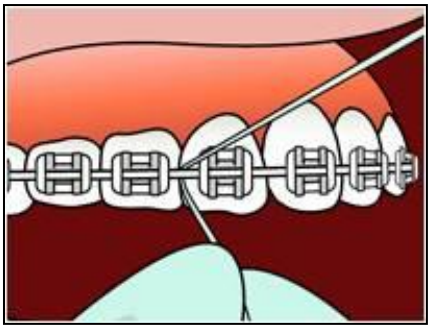

Figure 4-D: Floss around each tooth.

Anti-Plaque Agents: In addition to toothbrushes number of agents as Stannous fluoride, Tryclosan, Chlorhexidine and Listerine help to maintain the hygiene. Stannous fluoride gels are found to be more effective against gingivitis. It is found to be very useful to prevent decalcification in orthodontic patients by using daily, topical and in low concentration of 0.05% or 0.4% in gel form.[11] Continued use for 6 months after appliance removal helps to remineralize areas of decalcification that may have occurred during treatment. It was found 15-20 % patients develop mild staining with its use in 3-6 months of use, but yet its effectiveness largely depends on patient's compliance.

Listerine rinse contain 26% alcohol and should be rinsed twice daily for one minute for anti-gingivitis effect without dilution. Tryclosan toothpastes have good anti-gingivitis effect, good taste and good control against supragingival calculus. They should be the standard toothpastes for all orthodontic patients with fixed appliances.[12] Chlorhexidine has always been the best option in management in severe gingivitis in adolescent patients. A three month use of 0.12 % chlorhexidine approximately reduced 65% plaque, 77% gingival bleeding.[13] One of the main problems with its use was potential staining [Figure 6].

Few products such as baking soda toothpastes which might also contain peroxides are marketed as antiplaque agents. If fluoride content is present, they too can be used for orthodontic patients. Sanguinaria, baking soda and peroxide used as antiplaque agents are not FDA or ADA approved.[14, 15]

Oral irrigator with regular tap water at high pressure with a conventional irrigator tip can aid as a very effective method in periodontal maintenance. Use of chlorhexidine with specially modified irrigating tips called as '*Pik Pocket* (Teledyne Corporation)' can be used to directly to irrigate the pockets with medium pressure if gingival bleeding on probing persists [Figure 7]. [16]

Decalcification Treatment

Decalcification is evident in form of white or yellow stains clinically with possible roughness. Best method to prevent is use of fluoride toothpaste without rinsing with water or by using a topical fluoride rinse or gel twice daily during orthodontic treatment. This regime helps in 50% reduction in discoloration. For stains still present after 6 month, a rotary green bur may be used to remove a thin layer of decalcified enamel. This may additionally remove 25% of the stains.

Post orthodontic treatment, moderate decalcified areas may present as larger areas of color changes in yellow-brown form with definite roughness [Figure 8]. But when a severe decalcified area is present, patient might have to have a restoration placed.

To prevent these problems few steps by the clinicians, as bonding of molars than banding, in periodontal compromised patients can be helpful. Use of single archwires whenever possible and removal of excess composite around brackets, especially at gingival margins can aid in additional maintenance.

Gingival Recession

Gingival recession is found to be more in periodontally compromised patients undergoing orthodontic treatment [Figure 9]. A clinician should be aware of this fact and have an interdisciplinary treatment plan. Force applied on periodontally compromised teeth can result in more periodontal breakdown and regeneration of such periodontal ligament tissues is difficult. As a result, with loss of bone support, centre of resistance of the involved tooth moves more apically resulting in teeth being more prone to tipping movements than required bodily movements [Figure 10]. Supra gingival plaque can shift to subgingival position in a plaque infected tipped/tilted teeth inducing an apical shift of the connective tissue attachment and formation of pockets and further loss of attachment. Due to risk of having more PDL attachment loss, very light forces must be applied.[17]

Areas of thin gingiva are usually noted as having washboard appearance of prominent roots and a narrow width of attached gingiva. Tooth movement if in labial direction, may require soft tissue graft. If teeth having thin tissue are going to be moved



Figure 5: Electric tooth brush- ROTADENT



Figure 6: Chlorhexidine stains



Figure 7-A: Oral irrigator.



Figure 7-B: Oral irrigation to gingival pockets.



Figure 8: Decalcification post orthodontic treatment.



Figure 9: Gingival recession during orthodontic treatment.

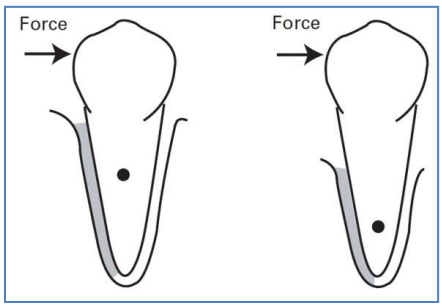

Figure 10: Apical shift of centre of resistance in bone loss

lingually, there is potential for the tissue to move coronally and become thicker. In this case any grafting of soft tissue should be postponed until active tooth movement is completed. In cases of bony defects, teeth can be moved orthodontically provided the remaining bone and periodontuim are brought to healthy states.[18,19]

Retention

Post orthodontic treatment removable or fixed retainers are necessary to prevent any relapse of the treatment and allow time for reorganization of the gingival and periodontal tissues.[20] As instructed by the clinician, patients should be made aware of its importance and motivated for proper use of retainers to avoid any possible damage to the tissues [Figure 11].



Figure 11-A: Permanent lingual retainer given post orthodontic treatment on mandibular anteriors.



Figure 11-B: Relapse following no retainer use

Conclusion:

Treatment of orthodontic patients should have an interdisciplinary approach, to provide the best treatment plan to the patients. Patients should be explained all the modalities of treatment procedure and their effects on the gingiva and periodontuim and creating a positive reinforcement, motivate them for its maintenance and promotion of healthy oral health.

Referances:

1. Zachrisson BU: Cause and prevention of injuries to teeth and supporting structures during orthodontic treatment, Am J Orthod 69:285-300, 1976.
2. Kloehn JS, Pfeifer JS: The effect of orthodontic treatment on the periodontuim, Angle Orthod 44:127-134, 1974.
3. Wennstrom JL, Stokland BL, Nyman S, Thilander B. Periodontal tissue response to orthodontic movement of teeth with infrabony pockets. Am J Orthod Dentofacial Orthop 1993;103:313–9.
4. Nakamura Y, Tanaka T, Noda K, Shimpo S, Oikawa T, Hirashita A, et al. Calcification of

degenerating tissues in the periodontal ligament during tooth movement. J Periodont Res 2003;38:343–50

5. Eliasson LA et al: The effects of orthodontic treatment on periodontal tissues in patients with reduced periodontal support. Eur J Orthod 4:1-9, 1982.
6. Boyd RL et al: Periodontal implications of orthodontic treatment in adults with reduced or normal periodontal tissues versus those of adolescents. Am J Orthod Dento-facial Orthop 96:191-199, 1989.
7. Alstad S, Zachrisson BU: Longitudinal study of periodontal condition associated with orthodontic treatment in adolescents. Am J Orthopd 76:277-286, 1979.
8. Boyd RL. Mucogingival considerations and their relationship to orthodontics. J Periodontol 1978;49:67-76.
9. Boyd RL, Murray P, Robertson PB: Effect of rotary electric tooth brush veraus manual toothbrush on periodontal status during orthodontic treatment. Am J Orthod Dentofacial Orthop 96:342-347, 1989.
10. Boyd RL, Rose CM: Effect of rotary electric tooth brush versus manual toothbrush on decalcification during orthodontic treatment. Am J Orthod Dentofacial Orthop 105:450-456, 1994.
11. Boyd RL, Leggot P, Robertson PB: Effects on gingivitis of two different 0.4% SnF_2 gels. J Dent Res 67:503-507, 1988.
12. Volpe AR et al: a review of plaque, gingivitis, calculus and caries clinical efficacy studies with a fluoride dentrifice containing triclosan and PVM/MA copolymer, J Clin Dent &(suppl):1-14, 1996.
13. Brightman LJ et al: the effects of a 0.12% chlorhexidine gluconate mouthrinse on orthodontic patients aged 11 through 17 with established gingivitis. Am J Orthod Dentofacial Orthop 100:324-329, 1991.
14. Marshall MV, Cancro LP, Fishman Sl: Hydrogen peroxide: a review of its use in dentistry. J Periodontol 66:786-796, 1995.
15. Harper DS et al: Clical efficacy of a dentrifice and oral rinse containing sanguinaria extract and zinc chloride during 6 months of use. J Periodontol 61:352-368, 1990.
16. Eakle W et al. Penetration of periodontal pockets with irrigation by a newly designed tip. J Dent Res.67(special issue):400, 1998.
17. Burstone CJ. Application of bioengineering to clinical orthodontics in Orthodontics. In: Graber TM, Vanarsdall RL, editors. Orthodontics: current principles and techniques. 2nd ed., St. Louis: Mosby; 1994. p. 235–67.
18. Boyd RL. Mucogingival considerations and their relationship to orthodontics. J Periodontol 1978;49:67-76.
19. Wennstrom JL: Mucogingival considerations in orthodontic treatment. Semin Orthod 2:46-54, 1996.
20. Blake M, Bibby K. retention and stability: A review of the literature. Am J Orthod Dentofacial Orthop 114:299-306, 1998.

Corresponding Author

Dr. Fulari Sangamesh G
Dept. of Orthodontics and Dentofacial Orthopedics, Maratha Mandals N. G. H Institute of Dental Sciences and research Centre Belgaum,Karnataka, India.
E-mail: *sangudr@gmail.com*