STRAIGHT TALK about CROOKED TEETH

This is fifth in a series of articles by

Derek Mahony, BDS, MDSc and **S. Kent Lauson,** DDS, MS (Orthodontists)



Derek Mahony



S. Kent Lauson

This is the fifth in a series of articles, which highlight information taken from the new book "STRAIGHT TALK about CROOKED TEETH" by Dr S. Kent Lauson, Orthodontist, Aurora, Colorado, USA, with a forward by Dr Derek Mahony, Orthodontist, Sydney, Australia. The book was written for the orthodontic consumer who typically would be a parent of a child with a developing malocclusion and the family dentist and orthodontist they see. The first four articles in this series dealt with the first four of the Nine Keys to Lower Facial Harmony, as presented in the book.

Those first four keys were as follows: Key # 1: Fully Developed Upper Jaw, Key # 2 Unobstructed Nasal Breathing, Key #3 Proper Forward Positioning of the Lower Jaw and Key # 4: Healthy TMJ Function. We presented the rationale as to why each of these keys are important in having not only a great orthodontic result, but a much healthier life for the patient, after orthodontics. The next Keys to Lower Facial Harmony that will be addressed in this article are Key # 5 Ideal Head Posture and Key # 6 Avoidance of Obstructive Sleep Apnea. The last three keys will be presented in the final article of the series.

Part I Key #5 Ideal Head Posture:

At first glance, you might question what a topic like Ideal Head Posture has to do with teeth. It is true that there is little discussion about head posture in the field of dentistry, and even less knowledge about the effect that teeth have on head posture. Nonetheless, teeth play a very important role in whether a person has a good or bad posture. Hopefully this article will make all dentists who read it, understand not only the relationship of teeth to posture, but how this can affect their day-to-day work as a dentist. Probably the most astute group of professionals, who understand the relationship of teeth to posture, are a small minority of physical therapists who have worked with dentists who treat TMJ Dysfunction and Obstructive Sleep Apnea.

We, in previous articles, wrote about the reflex action that occurs when a person has an overbite or a narrow upper jaw. The lower jaw becomes retruded by the trapping of it, by the narrow upper jaw. We wrote about how this may lead to TMJ dysfunction. In this article, we emphasize that this retraction of the lower jaw can also result in the head compensating by positioning itself in a more forward posture, conventionally referred to as a "forward head posture". This is a predictable compensation and over time results in a loss of normal lordosis (curvature) of the cervical spine. This is commonly called a "straight neck", or a "military neck", or just referred to as a loss of cervical lordosis. This unhealthy condition results in a loss of mobility of the neck and can also lead to mid and lower back dysfunction. It is indeed a serious problem that few people are aware of.

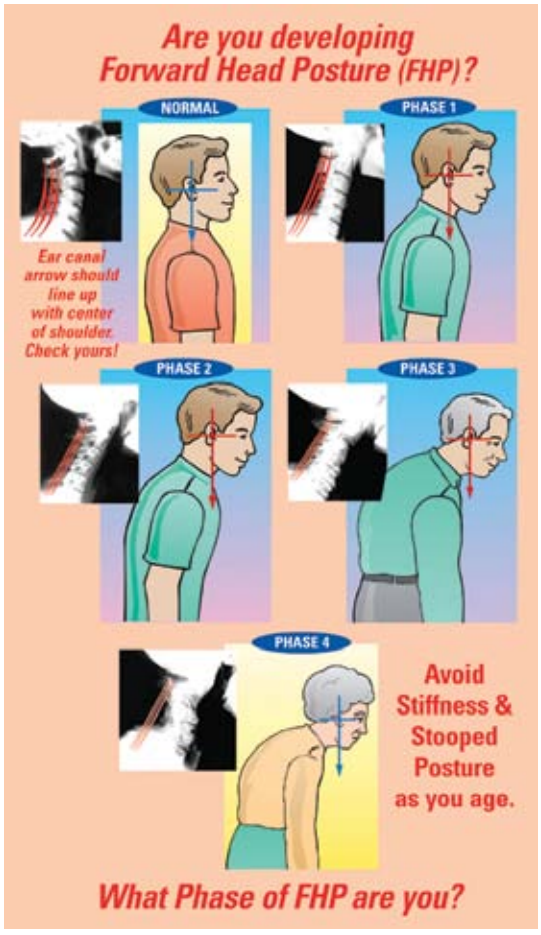

This illustration shows the progression of forward head posture and the loss of curvature (even reverse curvature, called kyphosis) of the neck and spine.

Although this fact is virtually unknown and ignored in medical literature, early treatment of dental malocclusions, such as overbites and constricted upper jaws, can have a very positive influence on a persons overall postural development.

The case below describes the recommended approach to correcting a very real developing problem. This 8 year old had underdevelopment of both upper and lower arches, and significant dental crowding, as a result. Among other problems, she already had clicking in her right TMJ and a loss of the normal curvature of her neck, with the characteristic forward head posture. Traditional orthodontic treatment may have had as many as four bicuspid teeth removed during the course of correction. This treatment would have been very detrimental, causing further developmental problems as this young lady ages.

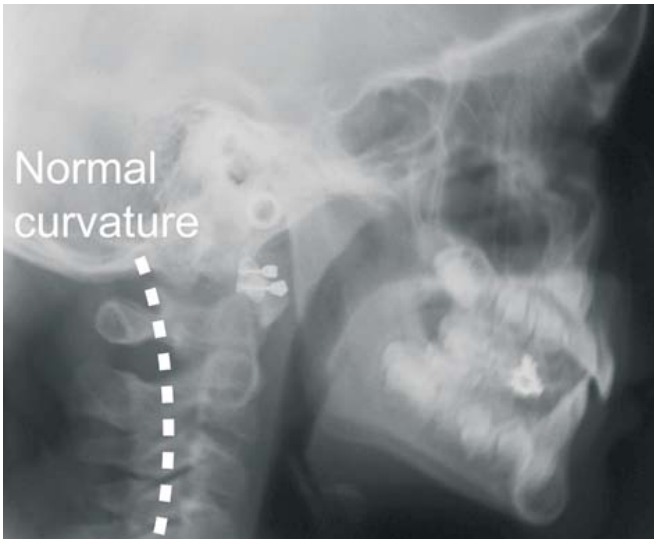

X-ray showing the loss of curvature of patient's neck

An initial phase treatment used functional facial orthopaedic (FFO) appliances to develop and enlarge the patient's bone structure. Details of the treatment appliances are described in the book. The following photos show the enhanced bone structure allowing for a straightforward non-extraction result:

A final phase of treatment using fixed braces completed her Phase 1 treatment. All the treatment issues were resolved, including the dental crowding (non- extraction treatment) the clicking TMJ, (TMJ Dysfunction) and the Forward Head Posture. The following photos were taken three years after the completion of her treatment. Her smile is full, broad and confident.

Part II Key # 6 Avoidance of Obstructive Sleep Apnea

Obstructive sleep apnea is another one of those conditions that doesn't seem obvious for inclusion in a book about children's orthodontics. As you have already seen with the keys for Healthy TMJ Function, and Ideal Head Posture, addressing problems within the mouth has a farther-reaching impact than simply what the teeth look like. Obstructive sleep apnea is another condition that can be affected by orthodontic treatment for better or worse.

Let's start by describing just what obstructive sleep apnea (OSA) is. OSA is the most common type of sleep disorder (among several types) and occurs when a person goes to sleep lying on his or her back. This promotes the back of the tongue resting too far back in the throat area. This can cause an obstruction of the air passageway, resulting in the stopping of airflow during breathing.

This restriction results in a lack of oxygen being delivered to the brain and usually causes the person to either wake up briefly or shift so that the blockage is relieved and air can flow again. It is called an apnea event if the stoppage lasts ten seconds or longer.


Pre-treatment photos


Progress photos before phase II orthodontic treatment


Photos after 3 years from treatment being completed



Normal Snoring OSA

Repeated events like this, throughout the night, are defined as obstructive sleep apnea and are classified as mild, moderate, or severe, depending on the age of the patient and the number of apnea events that occur per hour of sleep. It is considered very serious if a child has even a small number of apnea events because of their immediate effects and because this progressive disorder intensifies with age.

It has been well established that OSA creates cardiovascular stress, which can lead to strokes or heart attacks (with the possibility of death). OSA is also associated with many seemingly unrelated degenerative diseases, including pulmonary and systemic hypertension, diabetes, kidney disease, and ADD/ADHD. Studies show that a person with OSA has an average of twelve years cut off his or her life expectancy. It is known that as many as seventy-five million people, in North America, suffer from OSA; because of its widespread prevalence, it is a major health problem. In recent years, the lack of restful sleep and the resultant daytime drowsiness have been well documented. Now more motor vehicle accident deaths result from drowsiness than from drunk drivers.

OSA typically starts early in life as a mild obstruction and generally is accompanied by snoring. As the years pass by, if left unattended, the obstruction can progress into a sleep apnea problem. Although OSA is typically thought of as a problem for middle-aged, overweight males, the truth is that OSA can and does exist in a very broad range of the population. Young and old, male and female, large and small, all have the possibility of OSA. When a person has OSA, which is confirmed by an overnight sleep study, (performed at a sleep center facility with a sleep physician) the primary recommendation is to use a continuous positive air pressure (CPAP) machine. This device literally pushes air through a person's nose, all night long, to give him or her much needed oxygen as he or she sleeps. A secondary device, especially for those who are CPAP-intolerant, is an oral (dental) airway appliance used while sleeping. This device works by holding the jaw forward, which creates more room behind the tongue for air to flow.

During childhood, OSA can exist because of enlarged tonsils, adenoids, or any other obstruction that results in mouth breathing. OSA has been linked as a cause of ADHD, bed wetting, and even SIDS. When this airway obstruction is discovered, it must be removed right away, regardless of the age of the patient. A child with a deep overbite and a retruded, or recessed, lower jaw has a big, developing problem that needs early correction. A child with any nasal obstruction must have it eliminated.

A young person with a narrow upper jaw and developing overbite is already set up for possible future OSA. If the narrow upper jaw and overbite are not corrected in the ideal manner—by enlarging the constricted upper jaw and freeing up the lower jaw to come forward into the ideal position—the die is cast for OSA. An enlightened orthodontist, or dentist performing orthodontics, should recognize this fact and be instrumental in the prevention of a future OSA condition. This is a huge opportunity for proper progressive orthodontic treatment to eliminate the future problem of OSA and to give a lifelong benefit to the patient.

A nagging flaw in traditional orthodontic education exists. As a result of the removal of permanent teeth, the jaws are left in their less-than-ideal narrow state and a restriction of the upper-air passageway that exists is made worse by diminishing the airflow through it. This happens to be the first choke point in the airflow system, of the head and neck. The removal of teeth also causes the lower jaw to remain trapped in a retruded position, causing the airflow to the throat area (the second and final choke point) to also be reduced. Consequently, the removal of permanent teeth has a twofold effect, making the future likelihood of OSA much greater.

The Straight Talk book writes about orthodontic treatment objectives for young patients to prevent the development of OSA (and TMJ and neck problems) and is as follows:

1. Widen the upper jaw to an ideal full arch form (Key #1)
2. Make sure any nasal passageway obstruction is cleared (Key #2)
3. Encourage the lower jaw to grow forward to balance with the upper jaw (Key #3)

The goal of this treatment is to prevent the problem of OSA from developing later in life. It is our hope that when people seek help from an enlightened orthodontist, or dentist performing orthodontics, they may be offered the full benefit of these nine keys. In the next and final article of six highlighting the "Straight Talk about Crooked Teeth" book, we will discuss the last three keys of the Nine Keys to Lower Facial Harmony. These keys include Key #7, Ideal Lower Facial Symmetry, Key #8, Elimination of Adverse Oral Habits and Key #9 Optimal Teeth Positioning. Any dentist trained in orthodontics will recognize these final three keys as important. Stay tuned. ◆

