Table of Content

Advances in Caries Control----------2

Traditional methods for caries detection----------3
Fiberoptic transillumination----------5
Digital imaging FOTI----------5
QLF----------7
Laser infrared fluorescence----------8
Near infrared light----------9
Ultraviolet Illumination----------9
Penetration of dyes----------10
Optical coherence tomography----------10
Electrical resistance----------10
Cariescan----------11

Advances in Caries Control and Prevention----------12

Caries balance----------13
Use of pit and fissure sealants----------13
Decrease infection with cariogeneic bacteria----------14
Decreasing virulence of cariogenic bacteria----------14
Flouride----------14
Chlorhexidine ----------18
Casein phosphopeptide----------19
Xylitol ----------19

Dentine Hypersensitivity----------21

PEIRD----------23

References----------27

Advances in Caries Diagnosis:

Early diagnosis of caries has occupied particular importance these days since it has been proven in recent literature that these lesions can have the chance to remineralize before being grossly cavitated.

Dental caries is one of the most prevalent chronic diseases of humans worldwide. When different stages of the disease are taken into account, from the initial to the clinically manifest lesion, very few individuals are truly unaffected. In most industrialized countries 60%-90% of school-aged children are affected. The prevalence among adults is even higher and in most countries the disease affects nearly 100% of the population. [Karlsson 2010]

Diagnostic methods used commonly and widely these days include visual inspection, probe examination, traditional radiography and fiber optic transillumination . Some more recent methods include electrical resistance, laser fluorescence, and digital radiography.

Currently, the following methods are being developed: Fiber optic transillumination (FOTI), Light-scattering, Laser fluorescence, Ultra-violet illumination, Penetration of dyes, Electrical resistance, Ultrasonic imaging, and Improved radiographic imaging techniques.[Mansson et al.1993]

During the last thirty years the pattern of caries has changed, it has been slower in progression, this gives a chance to the dentist to have a control and stop the process if diagnosed early and truly. Complementing traditional diagnostic methods with advanced, more sensitive methods will improve caries diagnostic routines and hence the dental care and treatment of patients. [Karlsson 2010].

Traditional methods for caries detection:

The use of conventional diagnostic techniques seems satisfactory for the diagnosis of cavities but inadequate for the diagnosis of lesions **without cavities, lesions on the root surface or recurrent caries.**

A great discrepancy can exist among professionals when diagnosing occlusal caries without cavities therefore, clinicians' judgment is essential. Visual examination is most useful in detecting smooth surface caries, but is often obscured by plaque or salivary contamination of the tooth structures. A major problem is possibility of producing irreversible traumatic enamel defects in demineralized occlusal fissures during probing hence the use of blunt probe is recommended.
Caries is detected radiographically only in the advanced stages when there is sufficient decalcification of tooth structures. Not representative of its actual size, that is, it is much larger clinically than seen on a radiograph. Ordinary bitewing radiographs cannot differentiate between active and arrested lesions. Occlusal caries radiography is ineffective for detection until it reaches the dentin.

Barberia et al 2008 found in their study that the number of false-positive findings found between permanent molars were more than that found in primary molars. This could be because the dentists find it easier to use visual exploration to diagnose occlusal caries in primary molars, given the characteristics of their occlusal morphology and their anterior location in the arch. No differences in sensitivity and specificity values between the groups of maxillary and mandibular molars, which is similar to the results obtained by Heinrich-Weltzien and colleagues.[Barberia et al 2008]

Caries detection methods based on changes in a specific optical property are referred to in the literature as optically based methods, optical methods, or dental tissue optics. The methods are based on the measurement of a physical signal, derived from the interaction of light with dental hard tissue. In its simplest form, caries can be described as a process resulting in structural changes to the dental hard tissue. **The diffusion of calcium, phosphate, and carbonate out of the tooth, the demineralization process, will result in loss of mineral content. The resultant area of demineralized tooth substance is filled mainly by bacteria and water. The porosity of this area is greater than that of the surrounding structure. Increased scattering of incident light due to this structural change appears to the human eye as a so-called white spot. Hence, the caries process leads to distinct optical changes that can be measured and quantified with advanced detection methods based on light that shines on and interacts with the tooth. [Karlsson 2010]**

Karlsson described several methods under this section as mentioned in the following table:

Table 1: Summary of optical caries detection methods.

Optical Coherence Tomography Polarized Raman Spectroscopy
Polarization Sensitive Optical Coherence Tomography Fibre Optic Transillumination
Quantitative Light-induced Fluorescence Laser-induced Fluorescence
Transillumination with Near-Infrared light Infrared fluorescence
Near-Infrared reflectance imaging Terahertz Pulse
Imaging Multiphoton imaging Time-Correlated *Single-Photon Counting Fluorescence Lifetime*

Fiber optic transillumination ;

Fiber optic transillumination, **FOTI, has been designed for the detection of approximal caries. The basis for FOTI is that the decayed tooth material scatters light more strongly, and thus has a lower index of light transmission than a sound tooth structure**.[Mansson et al 1993]

Heinrich *et al.* (1991) compared FOTI with clinical and radiographic diagnoses of approximal caries in posterior teeth and found a sensitivity of 0.68 for FOTI and a specificity of 0.99 when radiography was the validating criterion.

Palmadibb et al in 2000 conducted a study to compare in vivo the accuracy of three diagnostic methods; clinical examination (light and mirror); bitewing radiographs, and fiber optic transillumination for detection of occlusal carious lesions in permanent teeth. The premolars and first molars of 58 subjects (aged 12-37 years) were examined by three gauged examiners. **A high degree of agreement among the methods assessed was observed in dentine, particularly between Fiber optic transillumination and X-ray that presented the highest concordance. Although not able to diagnose lesions confined to enamel, Fiber optic transillumination and X-ray may be considered important complementary means for occlusal caries diagnosis.[Palmadibb et al 2000]**

Although FOTI is light depending, yet it is not classified as a new technology. The more recent technologies are described later.

Digital Imaging Fiberoptic Transillumination:

New detection devices such as Digital Imaging Fiber-Optic Trans- Illumination (DIFOTI) have been introduced to improve early detection of carious surfaces. DIFOTI uses fiber-optic transillumination of safe visible light to image the tooth light delivered by a fiber-optic is **collected on the other side of the tooth by a mirror system and fed to a digital electronic charge-coupled device.** Then the acquired data are sent to a computer for analysis with dedicated algorithms, which produce digital images that can be viewed by the clinician and patient in real time or stored for later use. [Young et al 2005]

It consists of two handpieces one for occlusal surfaces and one for smooth and interproximal areas, a disposable mouthpiece, a foot pedal for selecting the image of interest from the live pictures and a computer system to capture and store the resulting image.



Young et al 2005 conducted a clinical trial to assess if the DIFOTI can be usefull to detect early proximal lesions in comparison with other detection modalities and they concluded that DIFOTI technology should not be used to decide between surgical or chemical treatment strategies based on lesion depth. They found also that F-speed radiographic films were accurate in approximating the depth of the lesion histologically. On the other hand, another clinical trial concluded that DIFOTI images correlated with clinical depth, especially in smaller lesions, and improved the estimation of lesion size when used in conjunction with the complementary metal oxide silicon (CMOS)-based digital radiographic sensor digital sensor and D-speed images since the statistical results of their trial revealed that the authors detected 84 percent of the lesions with DIFOTI, and 82 percent showed a visible dark shadow under the marginal ridge when examined clinically. DIFOTI correlated significantly with the clinical depth of decay. The combination of a CMOS digital sensor and DIFOTI provided readings closer to the clinical measures than did the combination of D-speed film and DIFOTI. [Bin-shuwaish et al 2008].

Quantitative Light-Induced Fluorescence "QLF":

Increased porosity due to a subsurface enamel lesion scatters the light either as it enters the tooth or as the fluorescence is emitted, resulting in a loss of its natural fluorescence. Bjelkhagen et al, Sundstr¨om et al., and subsequently de Josselin de Jong et al. developed a technique based on this optical phenomenon. [Karlsson 2010]

The quantitative light-induced fluorescence process involves two main stages: The first stage is the capture of the tooth image. Following this the resultant image must be analysed using the proprietary software supplied with the device to produce the final result, a measure of mineral loss.

The changes in enamel fluorescence can be detected and measured when the tooth is **illuminated by violet-blue light (wavelengths 290–450 nm, average 380 nm) from a camera hand piece, following image capturing using a camera fitted with a yellow 520nm high pass filter.** The image is captured, saved, and processed: it is first converted to black-and-white so that thereafter the lesion site can be reconstructed by interpolating the grey level values in the sound enamel around the lesion. **The difference between measured and reconstructed values gives three quantities: average change in fluorescence, lesion area (mm2), and a measure of the extent and severity of the lesion. Changes in fluorescence radiance and lesion area can be followed over time, to measure lesion development.** [Karlsson et al 2010]

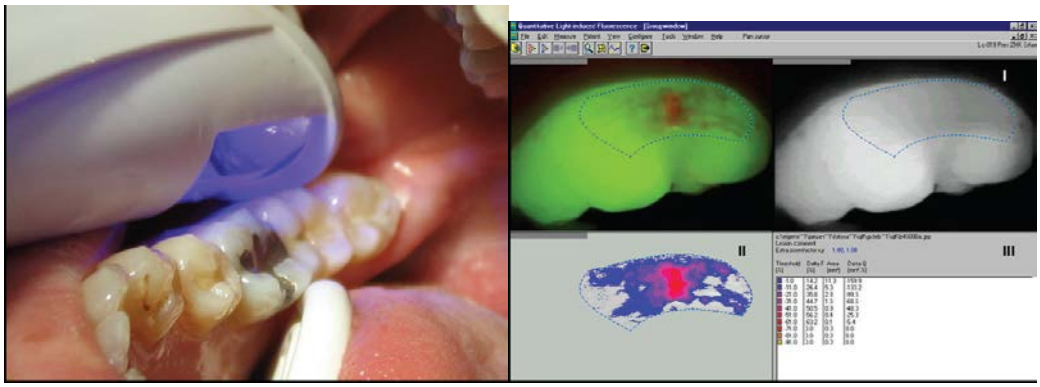

A clinical trial by Kuhnish et al 2007 comapring visual inspection with QLF concluded that QLF detects more non-cavitated occlusal lesions and smaller lesions. However, taking into consideration time-consuming image capturing and analysis, QLF is not really practical for use in the dental office. [Kuhnish et al 2007]

Laser Infrared Fluorescence System:

The operation of DIAGNOdent is based on the concept of stimulation of fluorescence through the use of laser light. This device produces a red light with a wavelength of 695 nanometers that the user applies to the dental surface.The light penetrates the enamel and the dentin, and the fluorescent light's intensity is measured by a photodiode and converted into digits, which appear on a screen. **Briefly, the device generates a laser beam that is absorbed by materials within the tooth and is subsequently re-emitted as infrared fluorescence. In the presence of carious tooth substance, fluorescence increases.**

Two versions of the laser fluorescence (LF) device are currently available commercially. **As well as the DIAGNOdent 2095 for application to smooth and occlusal surfaces, the latest version, the LF-pen (KaVo), has been designed for easier access to approximal surfaces. [Karlsson 2010]**





This device was put on the market in 1998, and various studies, both in vivo and in vitro, have evaluated its reproducibility, sensitivity and specificity with good results. [Barberia et la 2008]

Several studies and clinical trials stated that the laser device is a highly precise diagnostic tool for the **early diagnosis of occlusal caries in both primary and permanent molars,**

as well as for the verification of the effectiveness of remineralization treatments in incipient lesions. [Barberia et al 2008] [Zaidi et al 2010] In an in vitro study of primary molars, researchers demonstrated that the results obtained with DIAGNOdent by various examiners are more reproducible and homogeneous than those derived from visual exploration. [Bengston et al 2005].

The LF pen has performed as well as the original device on occlusal surfaces in vitro. To date, there is only one published study of the clinical performance of the LF pen on occlusal surfaces.[Karlsson et al 2010]

Transillumination with near-infrared light:

Methods that use longer wavelengths, such as in the NIR spectra (780 to 1550 nm), can penetrate the tissue more deeply. This deeper penetration is crucial for the transillumination (TI) method. Research has shown that enamel is highly transparent in the NIR range (750nm to 1500 nm) due to the weak scattering and absorption in dental hard tissue at these wavelengths. Therefore, this region of the electromagnetic spectrum is ideally suited to the development of new optical diagnostic tools based on TI.[Karlsson et al., 2010]

The method is nondestructive, non-ionizing, and reportedly more sensitive to detect early demineralization than dental X-rays. Identification of dental caries by TI is based on the fact that increased mineral loss in an enamel lesion leads to a two fold increase in scattering coefficient at a specific wave length. Karlsson et al summarized the advantages of NIR. It overcomes some of the limitations of dental radiography such as overlapping, **can indicate the relative position of a lesion on approximal surfaces by calculating the ratio of contrast values obtained by illuminating tooth from the lingual or buccal surface, respectively. The method uses a range of wavelengths where low-cost light sources are available and the transmitted image can be detected by an ordinary CCD camera, similar to the one in mobile phones.**

Ultraviolet Illumination:

Ultraviolet (UV) light has been used to increase the optical contrast between the carious region and the surrounding sound tissue. [Mansson et al 1993] The natural fluorescence of tooth enamel, as seen under UV illumination, is decreased in areas of less mineral content, such as in caries lesions, artificial demineralization, or developmental defects [Alfano and Yao, 1981]. The caries lesion appears as a dark spot against a fluorescent background.

Alfano and Yao had found that ultraviolet illumination was more sensitive than the simple visual/ tactile methods, although distinguishing between a carious lesion and developmental defects is the main problem.

Penetration of dyes:

Various dyes, fluorescent or non-fluorescent, have been used for staining the porous caries lesion in order to enhance the contrast between the carious region and the surrounding sound enamel. Rawls et al. (1978) used fluorescent dye uptake as an aid to early diagnosis of **smooth surfaces and approximal incipient lesions.** This fluorescence method showed very promising sensitivities and specificities. [Mansson et al 1993]

Different types of dyes have been introduced like, sodium fluorescein, potassium iodide and fluorol but all of these dyes should be approved for human use before clinical application starts. Limited literature is available for this method.

Optical coherence tomography:

This method of imaging that has been developed for transparent and semi-transparent structures. In the past 6 years, interest in the uses of OCT for dental imaging has grown [Baumgartner et al., 2000]

OCT technology is an imaging modality that provides a tool for noninvasive evaluation of tissue microstructure by providing high spatial resolution (10–20 m) and real-time, two dimensional depth visualization. The principle of OCT is similar to B-mode ultrasound imaging, except that OCT uses near infrared NIR light instead of sound. [Amaechi 2009]

Electrical Resistance "Electrical Conductivity Monitor":

The electrical resistance method is based on the assumption that electrical conductivity is a function of porosity. Enamel demineralization results in increased porosity, and saliva fills the pores and forms conductive pathways for electrical current. Thus, the greater the amount of demineralization, the higher the electrical conductivity through the affected enamel is expected to be.[Mansson et al., 1993]

ECM measures the electrical resistance of a site on the tooth during controlled drying. By drying the tooth surface, the resistance is determined by the tooth structure, avoiding electrical conductance by surface liquid saliva. **High measurements indicate well-mineralized tissue while low values indicate demineralized tissue. [Amaechi 2009]**

A major advantage of the ECM is to present objective readings, which have the potential for monitoring lesion progression, arrest, or remineralization.

Cariescan:

This device is based on the proven technology of **alternating current impedance spectroscopy and involves the passing of an insensitive level of electrical current through the tooth to identify the presence and location of the decay. The device is indicated for the detection, diagnosis, and monitoring of primary coronal dental caries _occlusal and accessible smooth surfaces_, which are not clearly visible to the human eye. It cannot be used to assess secondary caries, the integrity of a restoration, dental root caries, and the depth of an excavation within a cavity preparation.** Accompanying the CarieScan is the CarieScan-Plus, which is a wirelessly linked control system designed to be used as a patient management system, allowing data to be automatically captured, filed, and recalled electronically on a byt ooth, by-surface, by-date basis for dental health monitoring.

A systematic review comparing CarieScan with clinical visual examination, bitewing radiograph, and DIAGNOdent reported CarieScan to have a superior sensitivity and specificity ;both 92.5%,over other methods. [Amaechi at al 2009]





Advances in caries control and prevention:

Caries Balance:

The concept of the caries balance was first published by Featherstone in 1996 in an attempt to simplify the key factors involved in dental caries progression or reversal and make them readily applicable in clinical practice and easily understandable for the patient.

The caries process can easily be visualized as a balance between pathological factors and protective factors as shown in the figure. If the pathological factors outweigh the protective factors, then caries progresses. The balance is presented here with three key factors on each side. More detail could be added, but with experience simpler is better to enable students and practitioners to grasp and use the balance as a basis for understanding caries progression or reversal in individual patients. Step-by-step instructions for use in the clinical environment have been published elsewhere.

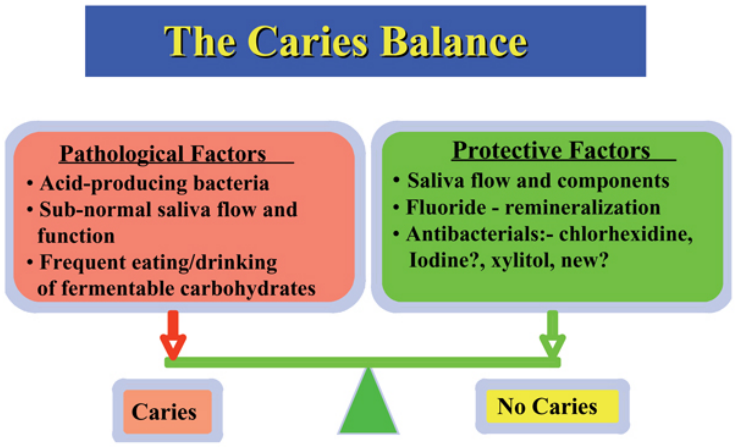

The above three pathological factors and three protective factors are not exclusive, but are the most important factors in assessing future caries risk and identifying why a person has caries or can be expected to show caries continue progression. Additional items including tooth morphology, oral hygiene, sealant application, and fluoride-releasing dental materials can be added, but the 3-vs-3 concept should be the first step in providing a risk assessment and an understanding of the caries process as it is progressing in an individual patient. [Featherstone. 2006]

The use of pit and fissure sealants:

The dental battle against decay in pits and fissures has a long and creative past that includes such preventive innovations as early physical blocking of fissures with zinc phosphate cement, mechanical fissure eradication, prophylactic odontotomy, and chemical treatment with silver nitrate. Creativity in this effort against fissure caries continues, with new materials and technologies tested each year.

As reviewed by Eklund and Ismail,during the 1950s, 1960s and 1970s, 70% of all molar occlusal surfaces became carious within 10 years of emergence into the oral cavity. A high percentage of these occlusal lesions occurred in the first 3 years after eruption. Therefore, it is faulty to emphasize sealant placement only within a few years of eruption. Sealant use must be based on personal, tooth, and surface risk, and this risk may change at any time in the life of the patient Sealant placement methods should include careful cleaning of the pits and fissures without removal of any appreciable enamel. Some circumstances may indicate use of a minimal enameloplasty technique. A low-viscosity, hydrophilic bonding layer as part of, or under, the actual sealant has been shown to enhance the long-term retention and effectiveness. Glass ionomer materials can be used a transitional sealants, and may prove to be effective as longer-term pit and fissure sealants. A tensile bond strength in the range 26–36 kg/cm^2 could be used as the base line value for comparison of new materials and procedures involving fissure sealants. Prophylaxis brush, add etching, and light-emitting diode light curing for 10 seconds seems to be the simplest and the most appropriate method of repair and is, therefore, recommended. [Feigal et al., 2002]

Sealants are effective in reducing occlusal caries incidence in permanent first molars of children, with caries reductions of 76.3 percent at four years, when sealants were

reapplied as needed. Caries reduction was 65 percent at nine years from initial treatment, with no reapplication during the last five years. [Feigal et al., 2002]

Decrease infection with cariogenic bacteria;

Dental caries is a common chronic infectious transmissible disease resulting from tooth-adherent specific bacteria, primarily mutans streptococci (**MS**), that metabolize sugars to produce acid which, over time, demineralizes tooth structure. MS generally is considered to be the principal group of bacterial organisms responsible for the initiation of dental caries. MS colonization of an infant may occur from the time of birth. Significant colonization occurs after dental eruption as teeth provide non-shedding surfaces for adherence. Other surfaces also may harbor MS. For example, the furrows of the tongue appear to be an important ecological niche in harboring the bacteria in predentate infants.

Vertical transmission of MS from mother to infant is well documented. Genotypes of MS in infants appear identical to those present in mothers in 17 reports.[AAPD] The higher the levels of maternal salivary MS, the greater the risk of the infant being colonized. Along with salivary levels of MS, mother's oral hygiene, periodontal disease, snack frequency, and socioeconomic status also are associated with infant colonization. Reports indicated also that horizontal transmission (ie, transmission between members of a group such as siblings of a similar age or children in a daycare center) also may be of concern. Dental caries is a disease that gene-rally is preventable. Early risk assessment allows for identi-fication of parent-infant groups who are at risk for ECC and would benefit from early preventive intervention. The ultimate goal of early assessment is the timely delivery of educational information to populations at high risk for developing caries in order to prevent the need for later surgical intervention.

Decreasing virulence of bacteria:

Dental caries, not unlike periodontal diseases, is now recognized as an infectious, transmissible, multifactorial disease of bacterial origin. Current evidence-based emphasis is on the need to recognize a carious lesion in its earliest stage before demineralization has produced a cavitated lesion that requires restoration by a dentist.

As a result of current understanding of caries control, the dental hygienist's role as a prevention specialist is to determine the dental caries risk factors for patients of all ages and to introduce remineralization strategies into the patient's dental hygiene care plan.

Conservative strategies of a concentrated program include initial infection control with a chlorhexidine rinse; extra daily fluoride exposures; placement of pit and fissure sealants where indicated; control of sucrose exposures; use of sugar substitutes, particularly xylitol-containing sugarfree chewing gum; and an emphasis on a daily bacterial plaque removal routine. Evidence supports the management and monitoring of dental caries. Caries risk level must be reevaluated at each maintenance appointment. Appropriate in-office strategies to preserve tooth structure should be carried out and followed by applicable home regimens that are based on need, not age. [Barber et al. 2002]

Several colleagues have advocated a combined fluoride-antimicrobial approach, In mechanistically simple terms, fluoride affects the level of enamel saturation (the 'critical pH'), while effective antimicrobials decrease the pH drop. This may be due to either inhibiting bacteria or reducing dental plaque. [TenCate's, 2010]

The effects of chlorhexidine are measured by various 'surrogate' output parameters, notably, general bacterial load, specific caries pathogens, acid production in plaque, demineralization of enamel in *in situ* models, or caries in randomized clinical trials (RCT). Chlorhexidine is used at different concentrations, up to 40% in varnishes. a meta-analysis combining the available studies on 0.05-2% CHX in rinses, gels, and toothpastes showed variable outcomes, but, on average, a caries-inhibiting effect of 46% [van Rijkom *et al*., 1996].

Many efforts are devoted to extracts from plants and natural products [Koo *et al*., 2005]. Also, photodynamic therapy has been developed, which combines a relatively inert dye that is photoactivated and then has bactericidal properties [Wood *et al*., 2006]. Antimicrobial peptides in saliva and their synthetic analogues have promising potential.

Replacement therapy has been researched for over 30 years, with cariogenic bacteria being modified to make them less acidogenic, while keeping their colonization-resistance properties [Hillman and Socransky, 1987]. Much of this work was started in the period when most attention was given to the arch criminal of caries, Streptococcus mutans. The

use of probiotics, very established in the treatment of intestinal diseases, is now also considered for oral diseases.

Effects of oral hygiene, chemotherapeutics (CPP, Xylitol, Chlorhexidine), dietary changes:

Home dietary counseling during infancy reduced the incidence of early and severe early childhood caries by 22% and 32%, respectively. [Feldens et al., 2010]

Decreased and delayed consumption of foodstuffs with high sugar density and a lower frequency of meals and snacks at 1 year represent possible mechanisms explaining these results, as these variables are strongly associated with childhood caries and sugar consumption practices established in infancy tend to be maintained through the first years of life. [Feldens et al.,2010]

On the other hand, despite improvement, a large proportion of children in the intervention group presented ECC and S-ECC. This fact and the fact that some targeted feeding practices did not differ across groups indicate that much needs to be learned about how best to promote healthy eating behavior. Analysis of the feeding practices showed higher compliance with the more objective ones, such as delaying the introduction of sugar, avoiding sweets and maintaining reasonable intervals between meals, perhaps more easily learned and followed by mothers and children. This program was not successful in promoting consumption of fruits and vegetables or reducing complex practices, such as night-time bottle use or use of bottle. [Feldens et al., 2010]

Oral hygiene counseling involves the parent and patient. Initially, oral hygiene is the responsibility of the parent. As the child develops, home care is performed jointly by parent and child. When a child demonstrates the understanding and ability to perform personal hygiene techniques, the health care professional should counsel the child. [AAPD]

With regard to tooth brushing, there only is a weak relationship between frequency of brushing and decreased dental caries, which is confounded because it is difficult to

distinguish whether the effect is actually a measure of fluoride application or whether it is a result of mechanical removal of plaque. [AAPD]

Fluoride is an important and effective means of reducing the caries incidence in children. Multiple fluoride products are available to dentists for use with their patients at risk for dental caries. Fluorides delivered through drinking water have a major role in decreasing caries. Forms of fluoride delivery are many including, dietary supplements, dentifrices, mouth rinses, self applied gels or pastes (5000 ppm), professionally applied gels or foams (12300 ppm), and fluoride varnishes (22600 ppm). AAPD recommended the use of these fluoride supplements according to the degree of the caries risk assessment of the patient. Adair 2006 has summarized the recommendations in a table according to evidence based literature as follows:

Adopted from Adair 2006, "Evidence based Use of Fluoride in Contemporary Pediatric Dental Practice "

Recommendations	Fluoride regimen
Assay patient's primary source of drinking water; consider other sources of fluoride intake Consider delaying supplementation until after eruption of permanent first molars Ensure that parents understand risks/benefits of supplementation Instruct patient to chew/swish supplement prior to swallowing Prescribe no more than 120 mg F No benefit to prenatal administration	Dietary supplements
Use in children <2 ys old should be based on caries risk assessment Tooth-brushing for young child should be done by adult; brushing by older child should be supervised by adult Use pea-sized dab of dentifrice in children with immature swallowing reflexes; older children can use larger amounts Brush with fluoride toothpaste twice daily	Dentifrices
Reserve for use in children with moderate/high caries risk Reserve for use in children who have mastered swallowing reflex Recommend alcohol-free preparations	Mouthrinses
Reserve for patients in fluoride-deficient communities who are at increased risk for caries Application should be done by adult for young child, and supervised by adult for older child Application period should be 4 minutes Allow patient to expectorate freely after application; postpone eating/drinking for 30 minutes Use with caution in children who have not mastered swallowing reflex Monitor effectiveness; terminate regimen when feasible	Self-applied gels/pastes (5000 ppm F)

Application frequency based on caries risk assessment Follow a pumice prophylaxis with fluoride application Use minimum amount of gel/foam necessary to cover teeth Seat patient upright, use suction to reduce swallowing of product Apply for 4 minutes Allow patient to expectorate freely after application; postpone eating/drinking for 30 minutes	Professionally applied gel/foam (12,300 ppm F)
Use after pumice prophylaxis as noted for gel/foam application Use in alternative restorative technique to arrest lesions in young, precooperative patients Have patient refrain from eating/drinking for 30 minutes after application Have patient postpone brushing teeth until following morning	Fluoride varnish (22,600 ppm F)

Chlorhexidine "CHX" has been shown in numerous studies to reduce the levels of mutans streptococci (MS) in the plaque biofilm in human mouths. Hence it is defined as an “antimicrobial”. It is much less effective at reducing the levels of lactobacilli (LB) in human mouths. [Barber et al,.2002]

CHX has two major characteristics; it is substantial; which means that it has the ability to maintain therapeutic activity for a prolonged period of time. The second characteristic is called adsorption because it adsorbs onto tooth surface, pellicle, plaque and mucous membrane. [Featherstone et al, 2006]
The strongest effect comes from the use of CHX varnishes, followed by gels, rinses follow both of these.[Barber et al.,2002]

Many regimens are reported in the literature, Barber et al reported in his evidence-based review that according to Andereason et al. the best recommended dose is that for two weeks the patient use a half ounce, 30 seconds rinse of 0.12% CHX just before bed. If this is the only treatment MS suppression will last 3 to 6 months. [Barber et al.,2002]

Casein Phosphopeptide "CPP" from the major protein of milk have the remarkable ability to stabilize calcium, phosphate and fluoride ions as water soluble amorphous complexes that provide bioavailable calcium, phosphate and fluoride ions to the tooth.
Three calcium phosphate-based remineralization systems are now available; a casein phosphopeptide stabilized amorphous calcium phosphate (Recaldent CPP-ACP), an

unstabilized amorphous calcium phosphate (ACP or Enamelon), and a bioactive glass containing calcium sodiumphosphosilicate (NovaMin).

Several randomized, controlled, double-blinded in situ clinical studies showed that: Sugar-free gums (CPP-ACP containing gums) were chewed for either 20-minute periods, four times a day or for 5-minute periods, seven times a day demonstrated that CPP-ACP nanocomplexes produced a dose-related remineralization of enamel subsurface lesions in situ and that CPP-ACP gum significantly slowed progression of caries and enhanced regression of caries compared with the control sugar-free gum.[Reynolds et al.;2008]

Studies related to mouthrinses showed marked increases in plaque calcium, phosphate and fluoride levels, and that calculus was not observed in any of the subjects. Indicating that the plaque calcium fluoride phosphate remained stabilized at the tooth surface by the CPP as bioavailable ions and did not transform into a crystalline phase. [Reynolds et al.,2008]

Xylitol is a five-carbon sugar alcohol derived primarily from forest and agricultural materials and is considered an antimicrobial and an antiacidic anticariogenic agent.

The early studies about xylitol effectiveness in dental plaque showed the decayed, missing, and filled (**dmf**) incidence in teeth in a sucrose chewing-gum group was 2.92 compared to 1.04 in the xylitl gum group. [AAPD]

A very comprehensive study conducted in 1995, compared the effect on caries incidence for xylitol, sorbitol, and sucrose consumption. The group that received 100% xylitol gum 5 times/day had significantly lower levels of sucrose and free sialic acid in whole saliva than at baseline and significantly lower plaque index scores. The xylitol group also exhibited the lowest levels of salivary lactobacilli at endpoint, and this group did not experience the age-related increase in Mutans streptococci (**MS**) as did the other groups. [Makinin et al.,1995]

Studies suggest xylitol regime that consistently produces positive results ranged from 4-10 grams per day divided into 3 to 7 consumption periods. Higher amounts did not result in greater reduction in incidence of caries and may lead to diminishing anticariogenic results. [AAPD]

Soderling et al. reported in his study that habitual xylitol consumption by mothers was associated with a statistically significant reduction of the probability of mother child transmission of MS assessed at 2 yrs of age. The effect was superior to that obtained with either CHX or fluoride varnish applications in that study.

Caries Vaccination rational is that immunization with S. mutans should induce an immune response, which prevent the organism from colonizing the tooth surface, and thereby prevent decay.

Bowen reported that monkeys remained caries free for more than 6 years after the animals received intraoral injections of killed S. mutans, even though the monkeys were fed highly cariogenic diets and had severe malocclusion that would predispose them to caries. [Bowen et al., 1996]

Timing of vaccination administration is best before the deciduous dentition has erupted at about 6 months of age. Immunity could be boosted at intervals thereafter to provide life-long protection andcould be given at the same time as the vaccines against diphtheria and tetanus. [Shivacumar et al., 2009]

Some rheumatic fever patients show serological cross-reactivity between heart tissue antigens and certain antigens from hemolytic Streptococci. For that to eliminate this possibility subunit or peptide vaccines have been used in systemic immunization to control dental caries.

Dentine Hypersensitivity

Dentin hypersensitivity can be defined as a temporary pain or exaggerated response from the exposed dentin to chemical, tactile, thermal or osmotic stimuli in the buccal environment, which would not normally occur in a healthy tooth. Under normal conditions, dentin is covered by enamel or cement and does not suffer direct stimulation. However, the exposure of dentin tubules due to enamel loss by abrasion, erosion, abfraction or root surface exposure caused by gingival recession, periodontal treatment or a combination of both may produce strong dentin sensitivity.

Several theories have been presented to characterize dentin hypersensitivity, but the hydrodynamic theory proposed by Brännström is the most widely accepted. According to its principles, the fluid movement inside the dentin tubules leads to sensorial activation of the nerve cells in the pulp, thus causing pain.

It has been reported that 8 to 30% of adults are affected by dentin hypersensitivity. Moreover, with more teeth being preserved and retained for longer periods, there will be an increasing demand by patients involved in this uncomfortable situation. Females have been reported to have a higher incidence of hypersensitivity than males, although the difference is not statistically significant, and the greatest incidence has been documented in the 20 to 40 year-old group. The most frequently affected teeth are premolars (68.8%), followed by molars, canines and incisors. [Assis et al., 2011]

There is no one way therapeutic technique or agent to treat DH. Many trials and experiments are reported in the literature. a new randomized controlled double blinded clinical trail found 0.454% SnF2 dentifrice provides significantly better immediate and ongoing sensitivity relief relative to a negative control dentifrice. [Procter et al., 2010] some authors has suggested the use of lasers to treat DH, but a randomized controlled trial concluded that none of the laser treatments studied was capable of completely

eliminating pain, but the Er:YAG and Er,Cr:YSGG lasers are suitable for the treatment of DH.[Paulo et al., 2011]

Sandhu et al., tried the use of "Iontophoresis"; iontophoresis is a technique wherei n desensitizing agents can be transferred under electrical pressure into the tooth structure to manage hypersensitivity. Their study tries three currents and they concluded that iontophoresis for all three current groups was almost equally effective, and it was found that repeated applications (up to three) gave good relief. Iontophoresis was found to be effective and safe. [Sandhu et al., 2011]

An interesting study has studied the effect of "propolis gel" in treating DH with comparison to potassium oxalate and fluoride gel. The conclusion of this study was that the application of 10% and 30% propolis gels did not seem to reduce the hydraulic conductance of dentin in vitro, but it showed capacity of partially obliterating the dentin tubules. Propolis is used in the treatment of different oral problems without causing significant great collateral effects, and can be a good option in the treatment of patients with dentin sensitivity. [Sales et al., 2011]

Pre-eruptive Intracoronal radioluscent Dentine lesions "PEIRD"

Dentine is a calcified tissue of the body, and along with enamel, cementum, and pulp is one of the four major components of teeth. Usually, it is covered by enamel on the crown and cementum on the root and surrounds the entire pulp. By weight, seventy percent of dentin consists of the mineral hydroxylapatite, twenty percent is organic material and ten percent is water.

Dentin consists of microscopic channels, called dentinal tubules, which radiate outward through the dentin from the pulp to the exterior cementum or enamel border. These tubules contain fluid and cellular structures. As a result, dentin has a degree of permeability which can increase the sensation of pain and the rate of tooth decay.

The formation of dentin, known as dentinogenesis, begins prior to the formation of enamel and is initiated by the odontoblasts of the pulp. Unlike enamel, dentin continues to form throughout life and can be initiated in response to stimuli, such as tooth decay or attrition.

There are different types of dentin, differentiated by appearance and stage of development. Primary dentin forms most of the tooth. Secondary dentin develops after root formation is complete and forms much more slowly than primary dentin. Tertiary dentin forms as a biological response to stimuli.

PEIRD lesions are radiolucencies in the dentin of crowns of unerupted teeth, may be observed incidentally on dental radiographs.These defects are usually initially located in the parts of dentin adjacent with the enamel on the occlusal parts of the dental crown. Although the lesions resemble dental decay and have been referred to as "pre-eruptive caries", these radiolucencies in unerupted teeth are unlikely to have resulted from caries

as they are not exposed to the oral microbial flora. Instead, they are likely idiopathic, developmental or resorptive lesions. [Seow et ls., 1998]

Although the pathogenesis of pre-eruptive dentin radiolucencies remains unknown, many case reports have provided clinical and histological evidence that these lesions are resorptive in nature. [Seow et al., 1999] The resorptive cells, which are likely to have originated from the surrounding bone, are thought to enter the dentin through a break in the external covering of the developing tooth. However, the etiology and factors associated with the initiation of the resorption are still unclear. [Seow et al., 1999] It has been suggested that local factors play an important role in the etiology. Ectopic positioning of affected teeth or the adjacent abutting teeth can cause local pressure that may be an inciting factor for resorptive cells to invade the dentin through enamel fissures or via the cementoenamel junction. Histological examination of the lesion's soft tissue revealed signs of resorption, including resorptive cells (osteoclasts and macrophages) and scalloped lesion borders.It has been suggested that this lesion might have originated as a developmental anomaly in which sections of the tooth failed to mineralize properly. This theory, however, has been subsequently disproved lately. [Davidovich et al., 2004] Pressure resulting from an abnormal position may induce sufficient local damage to the tooth's protective coverings to cause resorption cells to enter through the tooth and reach dentin. A lose of the integrity of the reduced enamel epithelium may allow osteoclasts, multinucleated giant cells, and chronic inflammatory cells to enter the tooth and initiate resorption of dentin. [Kupietz et al.,1999]

Diagnosis of these lesions usually occurs as accidental finding after taking a bitwing radiograph for a patient while examining something else. And because it has low prevalence (2-6 %) [Davidovich et al., 2004] it is usually misdiagnosed as artifact by dentists or not detected although apparent.

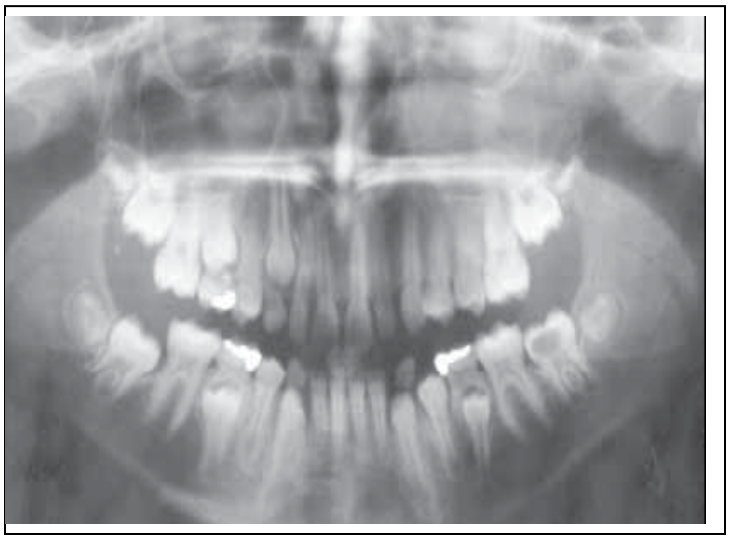

A large radiolucent area underneath the occlusal dent enamel junction of the mandibular left second molar on a panoramic radiograph taken for orthodontic reasons.

"Occult" or "hidden" caries refers to occlusal caries which is not diagnosed clinically because the occlusal surface appears ostensibly intact, and radiographs show radiolucencies in dentin. In spite of its relatively high prevalence, the etiology and pathogenesis of occult caries remain unclear. Some researchers hypothesizes that occult lesions could have resulted from processes which are pre-eruptive or post-eruptive. Pre-eruptive processes include intracoronal resorption of unerupted teeth, and the post-eruptive process is occlusal fissure caries. When affected teeth are fully erupted, it is difficult to determine if preeruptive resorption had been present previously. [Seow et al.,2000]

The management of PEIRD is varied and may consist of immediate surgical exposure with curettage of the defect or it may be possible to wait for the tooth to erupt to achieve occlusal access for restoration of the defect. The dental literature generally recommends surgical exposure of the unerupted tooth as soon as the lesion has been diagnosed radiographically to arrest the progression of the resorptive process and prevent its penetration into the dental pulp. Davidovich et al 2004 represented a case with this treatment approach and used glassionomer as the material for restoring resorbed dentin because of its less sensitivity to moisture in the described surgical field after surgical

exposure, and because of other important characteristic of glass ionomer mainly fluoride release into the cavity.

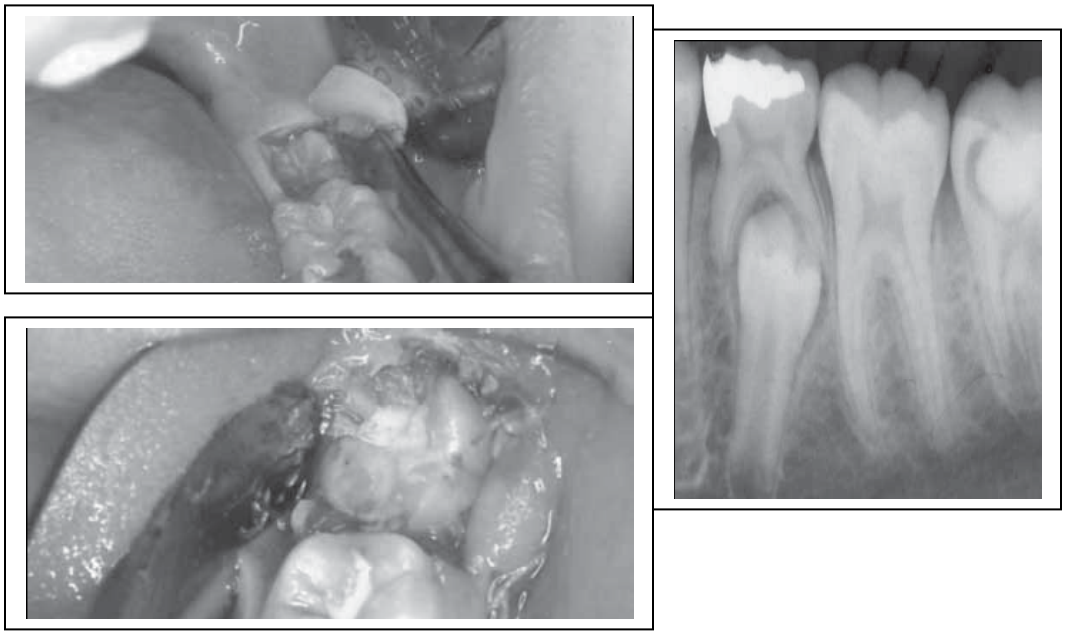

Failing to diagnose such lesions might lead to serious complications that might lead to loosing the tooth, it can easily penetrates the pulp, or more seriously it maight lead to fracturing of the whole crown and detachment from the root, Seow et al 1998 described in a case report a 2nd premolar tooth detached from its root during orthodontic debanding.

References

1. Featherstone J. Delivery challenges for fluoride, chlorhexidine and xylitol. BMC Oral Health 2006, 6(Suppl 1):S8.

2. Adair S. Evidence-based use of fluoride in contemporary pediatric dental practice. Pediatric Dentistry. 2006;28:133-142.

3. Barber L, Wilkins E. Evidence based prevention , management, & monitoring of dental caries. The Journal of Dental Hygiene. 2002;76:270-277.

4. Bowen W. Vaccine Against Dental Caries--A Personal View. Journal of Dental Research. 1996; 75:1530.

5. Young D, Featherstone J. Digital Imaging Fiber-Optic Trans-Illumination, F-speed radiographic film and depth of approximal lesions. Journal of American Dental Association. 2005;136:1682-1688.

6. Feigal R, Donley K. the use of pit and fissure sealants. Pediatric Dentistry. 2006;28:143-150

7. Barberia E, Maroto M, Arinas M, Silva C. A clinical study of caries diagnosis with a laser fluorescence system. . Journal of American Dental Association. 2008;139: 572-581.

8. Mansson B. Advances in Methods for Diagnosing Coronal Caries-a Review. Advanced Dental Research. 1993; 2:70-79.

9. Amaechi E. Emerging technologies for diagnosis of dental caries: the road so far. Journal of Applied Physics. 2009;105:102047.

10. Zaidi I, Somani R, Jaidkha S. In vivo effectiveness of Laser Flourescence compared to Visual Inspection and Intraoral Camera for detection of Occlusal caries. Indian Journal of Dental Science. 2010;6

11. Feldens C, Giugliani E, Duncan B, Drachler M, Vı´tolo M. Long-term effectiveness of a nutritional program in reducing early childhood caries: a randomized trial. Community Dentistry and Oral Epidemiol 2010; 38: 324–332.

12. Reynolds E. Calcium phosphate based remineralization systems: scientific evidence? Australian Dental Journal. 2008;53: 228-273.

13. Karlsson L. Caries DetectionMethods Based on Changes in Optical Properties between Healthy and Carious Tissue. International Journal of Dentistry. 2010; 9

14. Low T, Davies E, Fraunhoufer J. A method of determining the tensile bond strength of fissure sealant materials. Published online. 2007;

15. Mäkinen K, Benett C, Hujoel P. Xylitol chew-ing gums and caries rates: A 40-month cohort study. Journal of Dental Research .1995;74(12):1904-13.

16. Sales s, Carvalo N, Marsicano J. Effect of propolis gel on the in vitro reduction of dentin permeability. Journal of Applied Oral Science. 2011;19(4):318-23.

17. Aranha A , Paulo C. Effects of Er:YAG and Er,Cr:YSGG lasers on dentine hypersensitivity. Short-term clinical evaluation. Lasers Medical Science. 2011;

18. Sandhu S, Sharma R, Bharti V. Comparative evaluation of different strengths of electrical current in the management of dentinal hypersensitivity. Indian Journal of Dental Science. 2011;6

19. Assis A, Azivido L, Fonteles C, Colarese R. Dentin hypersensitivity after treatment with agents: a randomized, double-blind, split-mouth clinical trial. Brazalian Dental Journal. 2011;22
20. He t, Barker M, Sharma N. Fast onset sensitivity relief of a 0.454% stannous fluoride dentifrice. Journal of Clinical Dentistry. 2011;22:46-50.

21. Davidovich E, Kreiner B, Peretz B. Treatment of Severe Pre-eruptive Intracoronal Resorptionof a Permanent Second Molar. Pediatric Dentistry. 2005;27:74-77

22. Kupietzky A. Treatment of an undiagnosed pre eruptive intra-coronal radiolucency. Pediatric Dentistry. 1999; 21:6.

23. Seow W. multiple Preeruptive intracoronal radiolucent lesions in permanent dentition: a case report. Pediatric Dentistry . 1998; 20: 3.

24. Seow W, Wan A, McAllan H. The prevalence of pre-eruptive dentin radiolucencies in
25. the permanent dentition. Pediatric Dentistry. 1999; 21:1.

26. Seow W. Pre-eruptive intracoronal resorption as an entity of occult caries. Pediatric Dentistry . 2000; 22:5.

27. Bowen w. Vaccine against Dental Caries: a personal review. Journal of Dental Research. 1996 Aug;75(8):1530-3.
28. Soderling E, Isokangas P, Tenouvo J. Influence of maternal xylitol consumption on mother-child transmission of mutans streptococci: 6-year follow-up. Caries Research. 2001; 35:173-177.

29. Bin-Shuwaish M, Yaman P, Dennison J, Neiva G. The correlation of DIFOTI to clinical and radiographic images in Class II carious lesions. Journal of American Dental Association. 2008; 139;74-81.
30. Kühnisch J, Ifland S, Tranaeus S, Hickel R, Stösser L, Heinrich-Weltzien R. In vivo detection of non-cavitated caries lesions on occlusal surfaces by visual inspection and quantitative light-induced fluorescence. Acta Odontol Scand. 2007 Jun;65(3):183-8.

31. Baumgartner A, Dichtl S, Hitzenberger CK, Sattmann H, Robl B, Moritz A, Fercher AF, Sperr W. Polarization-sensitive optical coherence tomography of dental structures.Caries Res. 2000 Jan-Feb;34(1):59-69.

32. American Academy of Pediatric Dentistry Guidelines. Periodicity of Examination, Preventive Dental Services, Anticipatory Guidance, and Oral Treatment for Infants, Children, and Adolescents.

33. American Academy of Pediatric Dentistry Guidelines. Xylitol use in caries prevention.

34. American Academy of Pediatric Dentistry Guidelines. Infant Oral Health Care.