Sutures:

Establishing nontension primary wound closure of various soft tissue flaps is paramount for optimal postsurgical wound healing. Surgical procedures that require clinical flap manipulation, such as those used with traditional periodontal therapy, periodontal plastic cosmetic surgery, hard and soft tissue regeneration, and the excision of pathologic tissue, also require excellence in execution.

A good suture avoids that the displacing forces generated by the muscular insertions, functional movements and by the external agents destabilize or cause the surgical wound dehiscence.

If surgical wound edges are not properly approximated and are therefore inadequate, hemostasis is present and blood and serum may accumulate under the flap, delaying the healing process by separating the flap from the underlying bone. [Silverstein et al.,2009]

The wounds suture has old origins: the first description was found in a sixteenth century b.C. papyrus. They are works of the Greek doctor Hyppocrates the first traumatology texts that expounded the necessary rules for the treatment and for the wounds suture. In 1897, Joseph Lister points out that the threads sterilization with carbolic acid avoided the bacterial growth on them and so avoided the consequent tissues inflammation; a problem to take in examination on the post-operative course, because represents the main cause of surgical wounds healing delay. [Minozzi et al.,]

There are several classifications for sutures depending on their original material, number of threads, absorbability in the oral cavity. These classifications are summarized in the following illustration.

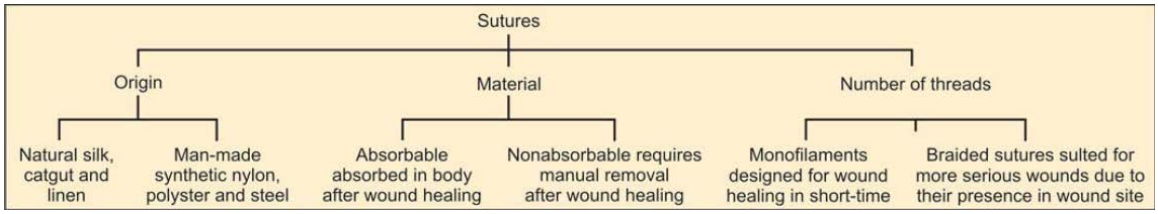

Suture materials are numbered according to their thickness from 1-0(0) to 9-0 (000000). The greater the number of zeroes, thinner is the material. Thicker suture are used for approximating deeper layers, wounds in tension prone areas and for ligation of blood vessels. Thin ones are used for closing delicate tissues like conjunctiva and incisions of face. [Manu mody ., 2009] With periodontal plastic surgery, a 5–0 thread diameter is most often used to secure soft tissue grafts and transpositional/ sliding pedicle flaps, whereas a 4–0 thread is used to secure most other periodontal mucoperiosteal flaps. In implant dentistry, a 3–0 thread diameter is usually used to secure flaps when a mattress suturing technique is placed, and then a 4–0 thread is used closer to the flap edges to coapt the tension-free flap edges. A 4–0 thread is also used to secure implant surgical flaps when interrupted sutures, some mattress sutures, and most continuous suture techniques have been performed. [Silverstein et al.,2009] [Howe 2nd edition]

Suture can be broadly divided into:

1. **Absorbable:** All suture materials that are digested by the body enzymes or are hydrolyzed by the fluids are absorbable.
2. **Nonabsorbable:** Sutures that cannot be digested by tissue enzymes and are encapsulated or walled are nonabsorbable.

These can be further divided into monofilamentous and multifilamentous in each category.

a. *Monofilamentous:* It is made up of single strand, resists harbouring micro-organisms and ties down smoothly.

b. *Multifilamentous:* It consists of several filaments twisted or braided together. This gives good handling and lying characteristics. The multifilamentous sometimes produce wicks (mainly silk) that may cause retrograde infection which the monofilamentous discourage.

Plain Catgut

Word catgut is derived from 'Kit gut' which means violin string. Catgut is derived from submucosa of the sheep intestines. Oldest suture material known. Plain catgut lasts for 7-10 days, hence its uses are minimal. It is biological, absorbable and monofilament. Surgical gut sutures may break too rapidly to maintain flap apposition, particularly if used in patients with a very low intraoral pH. [Silverstein et al., 2009] This material resists unchanged in the tissues for a period of time of approximately 8 days. Later it comes degraded within 30 days by enzymatic digestion mediated by the action of lymphocytes and macrophages.[Manu et al., 2009] [Minozzi et al.,]

The catgut is particularly indicated in the suture of deep structures (periosteum, subcutaneous tissue, vessels ligatures) and in the non collaborating subjects. It is contraindicated in the cases of delayed healing of the wounds.

Chromic Catgut

When plain catgut is mixed with chromic salts, chromic catgut is formed. Strength is for 15-25 days because of the added chromium salts [Minozzi et al.,]. It is biological, absorbable, monofilament. It has good knotting property. It is preserved in 70% alcohol and kept soft due to 5%

glycerine.

Vicryl

It is a copolymer of glycolide and lactide. It is a synthetic and absorbable suture. Unlike catgut this is absorbed by hydrolysis. It has better strength and reliability. It is synthetic so tissue reaction is less than that of chromic catgut. good knotting property.

Prolene

It is polypropylene and nonabsorbable. It is monofilament, artificial and uncoated.

Silk

Nonabsorbable, biologically derived from concoon of silkworm larva. Braided, coated with wax to reduce capillary action. Tissue reaction is more as it is a foreign protein inspite of this widely used because of easy availability and is cheap. Excellent knotting property.

Many manufacturers impregnate and cover the thread with waxes and silicones to reduce the capillarity, to increase the impermeability and the fluency. [Minozzi et al.,]

It offers disadvantages as a tissue reaction, correlated with the bacteria nidation in the filaments interstices, reason for which it is to avoid its employment in the presence of infected wounds, it is insufficiently resistant, few elastic and flowable. Therefore, because of its inflammatory reaction, is not agreable its employment in infected tissues. [Minozzi et al.,]

Needles

A surgical needle has 3 parts: the needle point, the needle body, and the swaged (press-fit) end (Figure 1). Suture needles are usually classified according to their curvature, radius, and shape. The most commonly used suture needles in dentistry are the 3/8 and 1/2 circle needles (Figure2). The 3/8 needle allows the clinician to pass from the buccal surface to the lingual surface in one motion by rotating the needle on a central axis. In contrast, the 1/2 circle needle is traditionally used in more restricted areas, for instance, in the buccal of the maxillary molars and the facial aspect of the maxillary and mandibular incisors. In addition, the 1/2 circle needle is routinely used for periosteal and mucogingival surgery. Suture needles are also classified as either conventional cutting or reverse cutting5 (Figure 3). In dentistry, clinicians should always use reverse cutting sutures to prevent the suture material from tearing through the papillae or surgical flap edges, which is referred to as a ‘‘cut out.’’ Usually, a cut out is caused by a conventional suture needle, because it has an inside concave curvature that is sharpened. A reverse

cutting needle, on the other hand, has a smooth inner curvature, and its third cutting edge is located on its convex (outer) edge.4 Generally in dentistry, the 3/8 reverse cutting needle with a 3–0 or 4–0 thread diameter and the 1/2 reverse cutting needle with the thinner and more delicate 5–0 or 6–0 thread diameter are the most commonly used needle-and-thread combinations, in the author's experience. [Silverstein et al.,2009]



FIGURES 1–3. FIGURE 1. Parts of the needle. A ¼ thread, B ¼ swag, C ¼ body, D ¼ point. FIGURE 2. Comparison of a 3/8 circle needle (bottom) and a ½ circle needle (top). FIGURE 3. Conventional cutting needle (left) and a reverse cutting needle (right).

In brief the most commonly used sutures in dentistry are classified in the following table:

Nonresorbable

- Silk
- Polyester
  - •Nylon
  - •PTFE

Resorbable

- Natural
  - •Plain gut
  - •Chromic gut
- Synthetic
  - •Coated Vicryl

Suturing techniques:

Silverstein et al **.,** 2009 have stated general guidelines for suturing; Sutures are usually placed distal to the last tooth, in each interproximal space, and suturing continues in a

mesial direction. _Sutures should always be inserted through the more mobile tissue flap first. _When space is restricted use a ½ circle needle. _Only needle holders should grasp suture needles, and the suture needle should be inserted and pulled through the issue in line with the circle. _Grab the suture needle in the center of the needle, never at its tip or near where the thread is swag to the needle. _The needle should be placed a few millimeters from the tip of the needle holder when grasped. _The goal during suturing multiple tissue levels is to suture periosteum to periosteum and gingival tissue to gingival tissue. _The needle should enter at right angles to the tissue when penetrating through tissues. _Sutures should be placed no closer than 2 mm to 3 mm from the flap edges to prevent tearing through the flap during postoperative swelling. The flaps should be approximated without blanching when sutured. Pull the suture just tight enough to secure the flap in place without restricting the flap's blood supply.

There are several techniques to form a suture, the most commonly one used in dentistry is the *simple interrupted suture* [Silverstein et al., 2009]; It is strong and can be used in areas of stress. Successive sutures can be placed according to individual requirement. An important advantage of this kind of sutures is each suture is independent and loosening of suture will not produce loosening of others and if the wound becomes infected or there is hemorrhage, removal of few sutures may be of satisfactory treatment. [Manu et al., 2009]

A *continuous suture* is when simple interrupted suture is placed and before tying the knot the needle is reinserted in continuous fashion that the suture passes perpendicular to incision below and obliquely above. The suture is then ended tying a knot over the untightened end of suture. It is a rapid technique. And it distributes tension uniformly over the suture line. [Manu et al., 2009] But once the suture knot has been released the whole suture thread will be released from the wound.

Another suturing technique, which is a variation of the interrupted suture, is the *mattress technique*. This technique is usually used in areas where tension-free flap closure cannot be accomplished. Mattress suturing techniques are generally used to resist muscle pull, evert the wound edges (this keeps epithelium away from underlying structures), and

adapt the tissue flaps tightly to the underlying structures (eg, bone graft, tissue graft, alveolar ridge, regenerative membrane, or dental implant). When using a mattress suture, usually a 3/8 reverse cutting needle is used with a thicker (3–0 or 4–0) thread diameter.1 Traditionally, mattress sutures are left in place for 14 to 21 days before dissolution or removal. [Silverstein et al.,2009]

Tying the knot

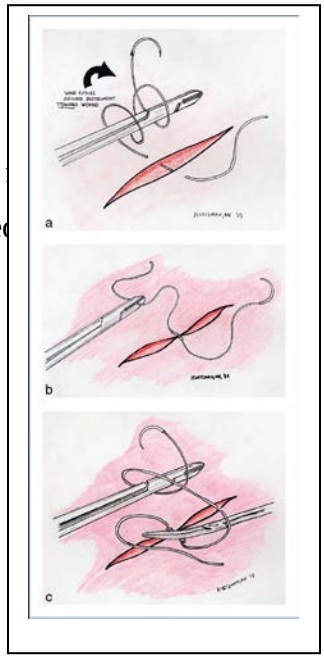

The steps of suture tying are described in the following steps:
(a) Surgeon's knot, step 1: the suture needle is wound around the needle holder twice in the direction of the wound. (b) Surgeon's knot, step 2: the end of the suture is grabbed with the needle holder and the knot is tightened to the tissue. (c) Surgeon's knot, step 3: the suture needle is wound around the needle holder once away from the wound, and then the free end of the suture is grasped and tightened, completing the knot. (Fig 4) [Pedlar & Johns 2nd edition]

Removal of sutures

Many patients are very apprehensive about suture removal, so the first step is to reassure the patient that the procedure is not painful. The tissue should be cleansed. Hydrogen peroxide is a good choice for gently removing dried blood and exudate. Then grasp one of the "ears" of the suture with a forceps to elevate the suture just enough to slip the tip of a small scissor under the suture in order to cut it. This should be done close to the skin/tissue edge in order to minimize the amount of contaminated suture that will be dragged through the stitch path. The suture is then gently removed by pulling with the forceps. It is frequently a good idea to reinforce the wound with Proxi-Strips or gauze packs. Proxi-Strips are narrow adhesive strips that are placed perpendicularly across the wound at intervals. [Manu et al., 2009]

The timing of suture removal depends on following factors:

a. The amount of wound tension at the time of closure. b. Whether subcutaneous sutures have been placed. c. The age and medical condition of patient. Location over stress sites. e. Patient medications. f. Presence of vascular disease. These factors necessitate longer time before removal. The suture is grasped with an instrument and lifted above the epithelial surface. The scissors are then passed through one loop and transected close to surface. The suture is then pulled out.

Skin sutures are usually removed after a period of 7-10 days and mucosal sutures are removed between 5-7 days. [Manu et al., 2009] [Howe 2nd edition]

References

Malik S. Textbook of oral and maxillofacial surgery.

Manu M. Critical Evaluation of Suture Materials and Suturing Techniques in Implant Dentistry. International Journ of Clini Imp Dent, 2009;1(2):31-40

Minozzi F, Bollero P, Unfer V, Dolci A, Galli M. The sutures in dentistry. Eur Rev Med Pharmacol Sci. 2009 May-Jun;13(3):217-26. Review.

Moore. Principles of oral and maxillofacial surgery. Fifth edition.

Silverstein L, Kurtzman G, Shatz P. Suturing for optimal soft tissue management. Journ of Oral Impla 2009; 2 :82-92.

Howe G. Minor Oral Surgery Textbook. 2nd edition.

Pedlar J, Frame J. Oral and maxillofacial surgery: an objective based textbook. 2nd edition.